

CASO N° 3

PAZIENTI DI 40 ANNI GIUNGE IN PS PER CARDIOPALMO DA 3 ORE.

PA 100/60mmHg, SATURAZIONE 99% IN AA.

ECG

VIENE CARDIOVERTITO ELETTRICAMENTE IN PS DAI COLLEGHI, RICOVERATO IN UTIC.

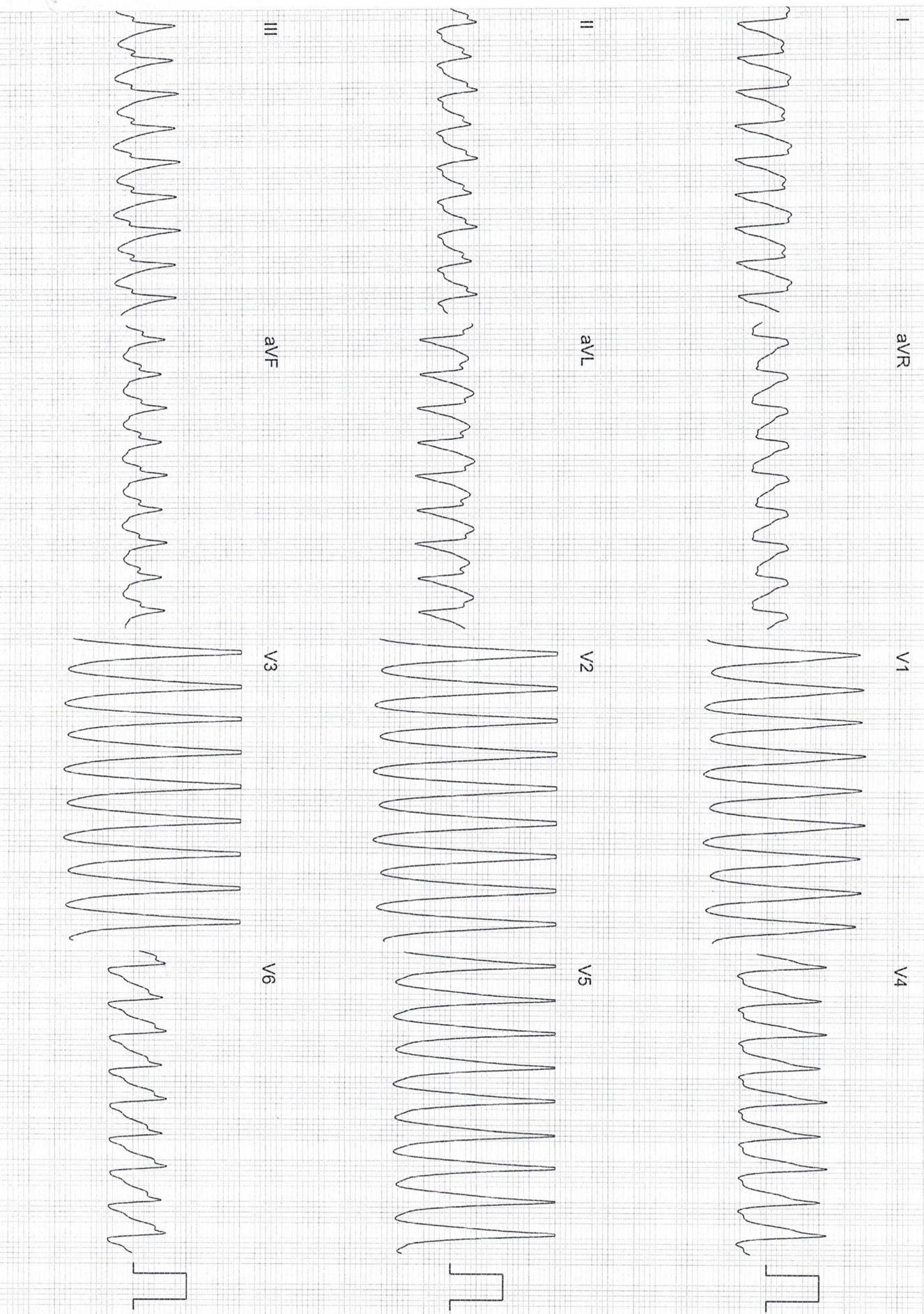
ECOGARDIOGRAMMA: SOSTANZIALMENTE NELLA NORMA.

CORONAROGRAFIA: CORONARIE INDENNI.

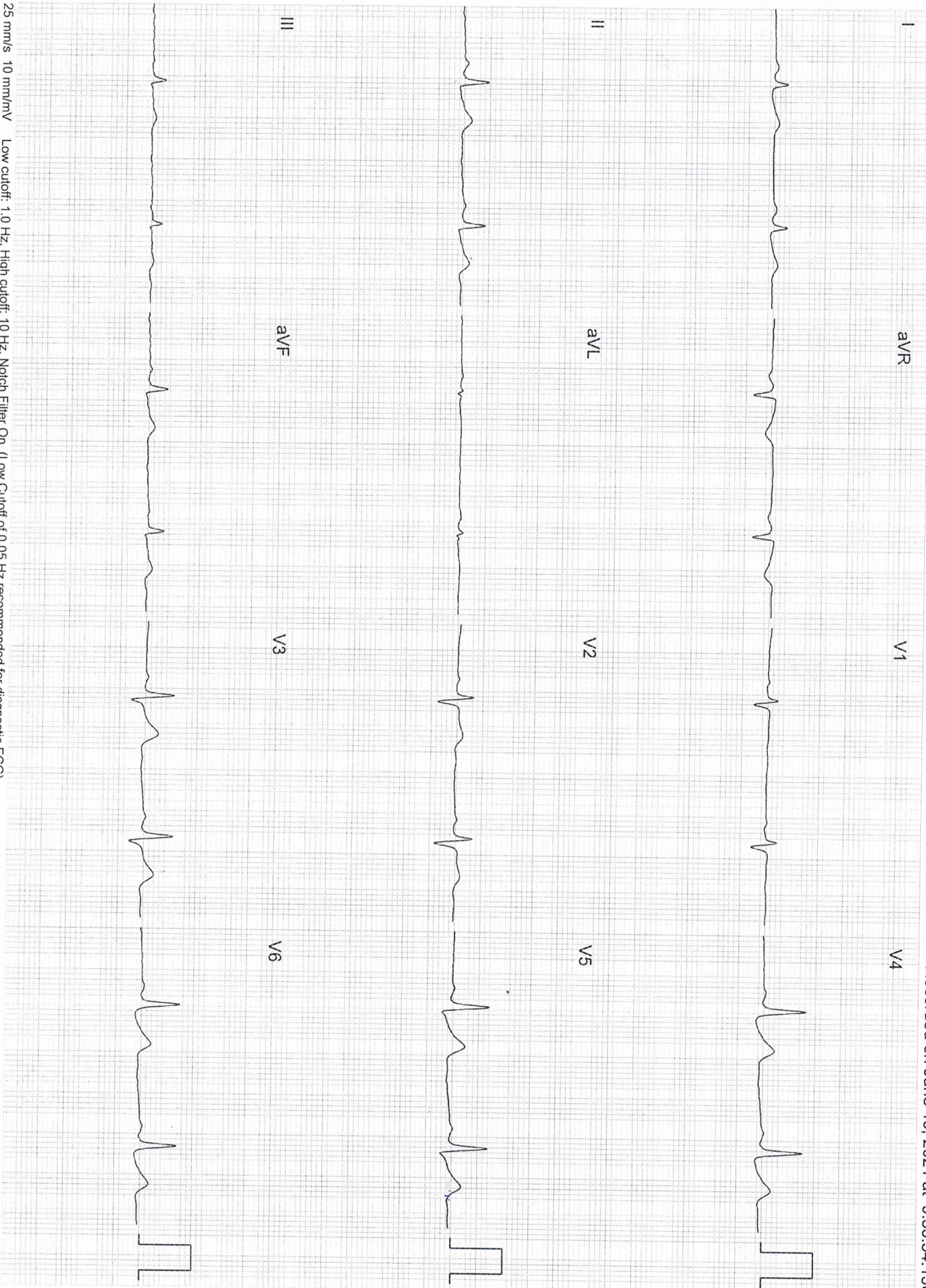
ESEGUE STUDIO ELETTROFISIOLOGICO

PERCORSO DIAGNOSTICO E CONSEGUENTE TRATTAMENTO

Three handwritten signatures in blue ink, arranged in a cluster. The top signature is the most prominent, followed by two smaller ones below it.



25 mm/s 10 mm/mV Low cutoff: 1.0 Hz, High cutoff: 10 Hz, Notch Filter On, (Low Cutoff of 0.05 Hz recommended for diagnostic ECG)



25 mm/s 10 mm/mV Low cutoff: 1.0 Hz, High cutoff: 10 Hz, Notch Filter On, (Low Cutoff of 0.05 Hz recommended for diagnostic ECG)

